

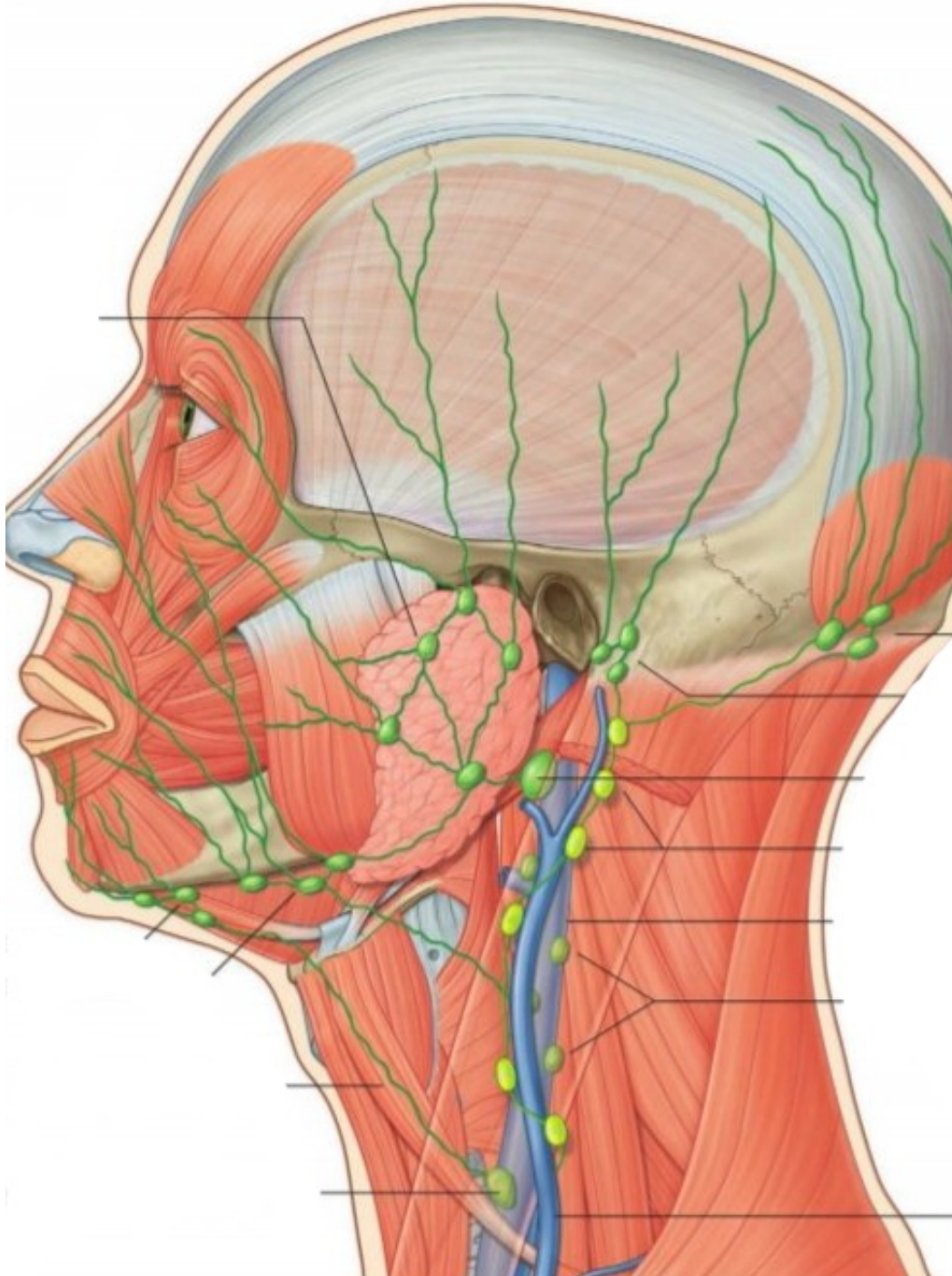


قائمة الاسئلة

تشريح الرأس و الرقبة مستوى أول - طب وجراحة الفم والاسنان

ديسرى شرف الدين

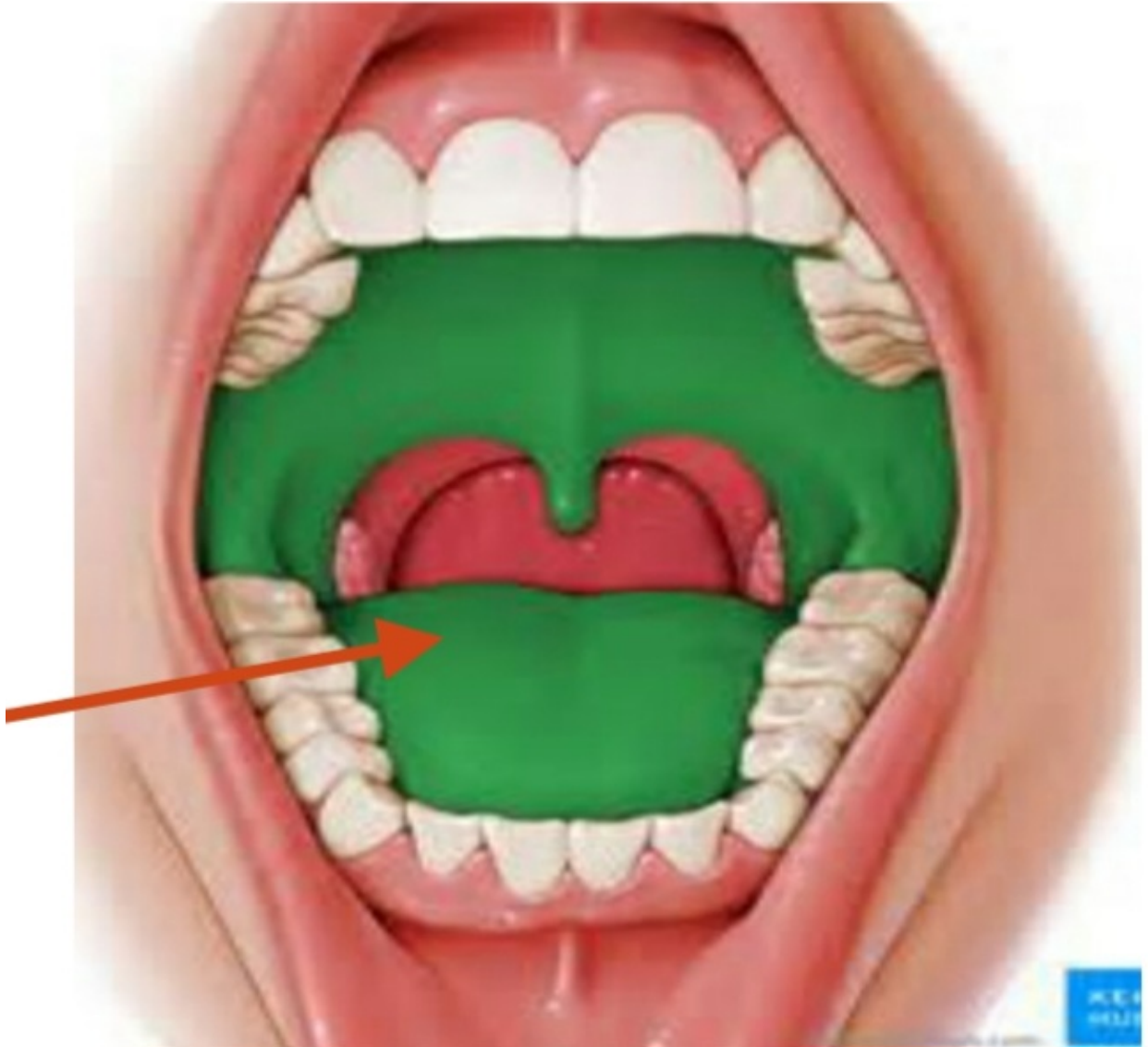
- 1) All of the following are lymph node in head expt:



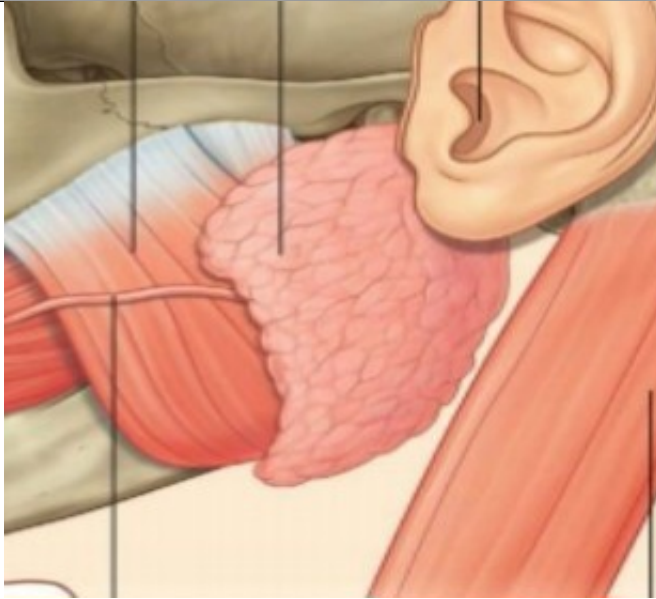
- 1) - Occipital



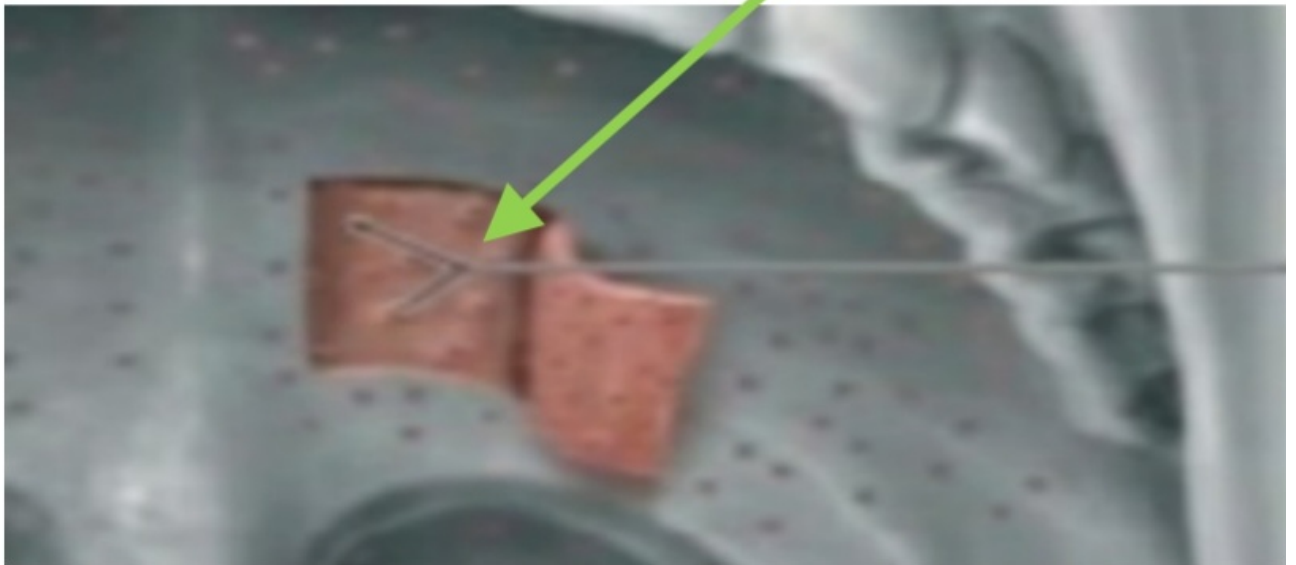
- 2) - Parotid
- 3)  Cervical
- 2) Name of this bart with green color is :



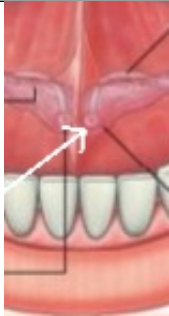- 1) - Oral cavity
- 2)  Oral cavity proper
- 3) - Oral vestibule
- 3) What is the name of this salivary gland:



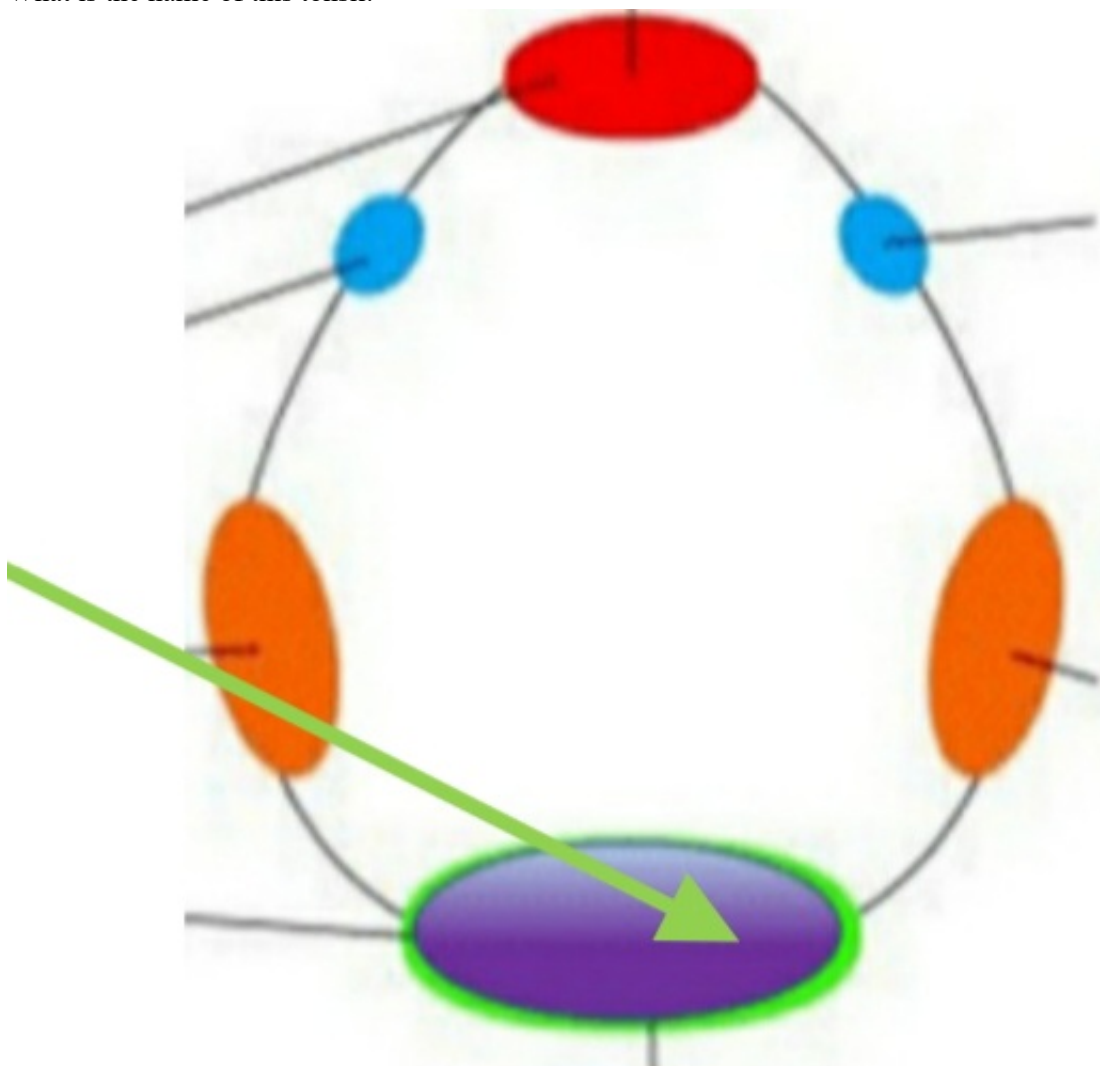
- 1) - Sublingual
- 2)  Parotid
- 3) - Submandibular
- 4) What is the name of this minor salivary glands:



- 1)  Palatine
- 2) - Labial
- 3) - Pharyngeal
- 5) This is opening for any of this salivary glands

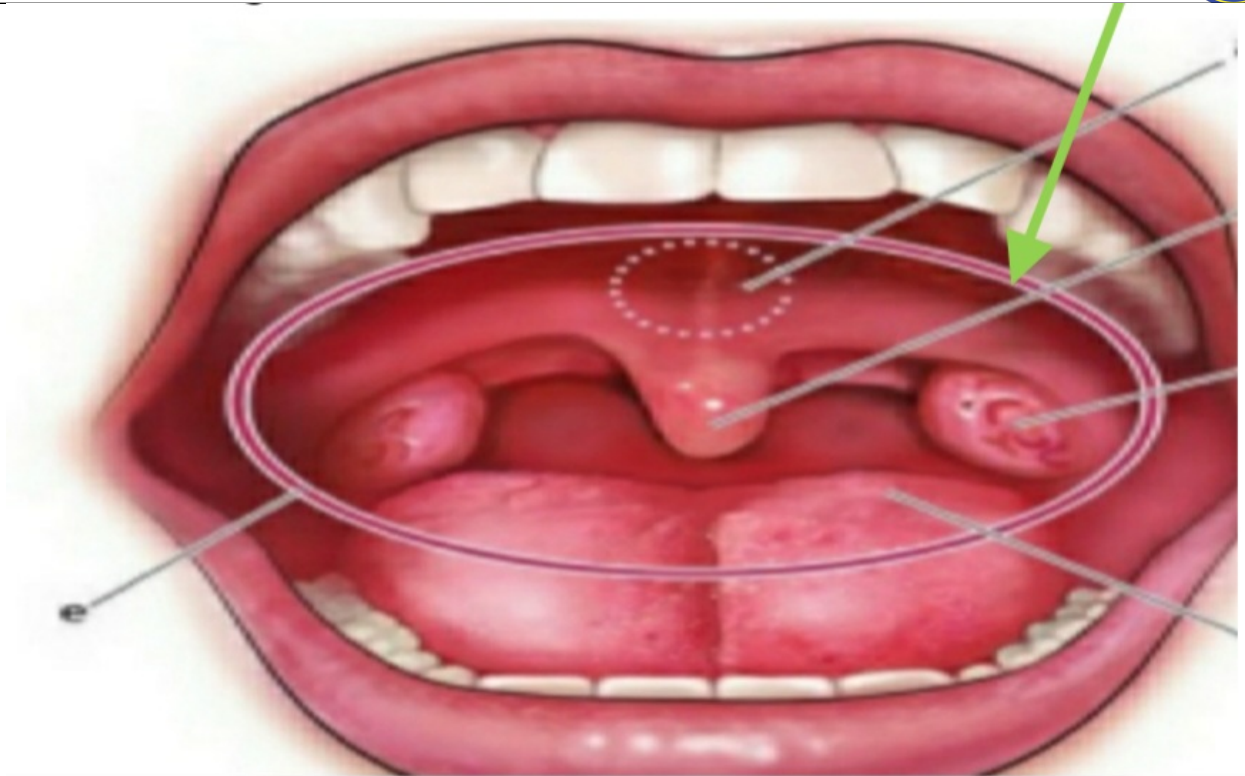


- 1) - Sublingual
  - 2) - Parotid
  - 3)  Submandibular
- 6) What is the name of this tonsil:

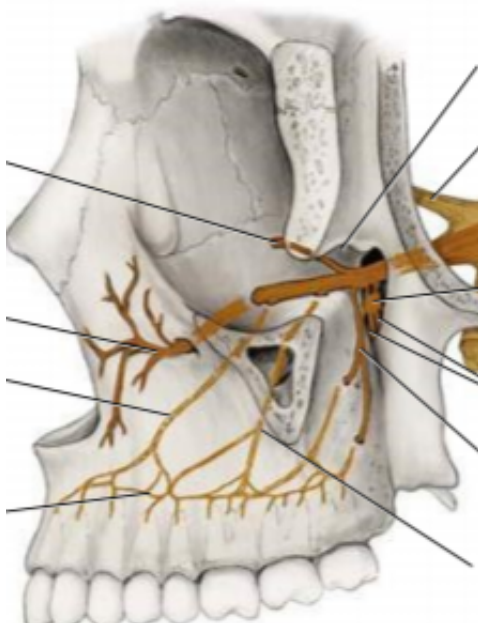


- 1)  Lingual
  - 2) - Palatine
  - 3) - Pharyngeal
- 7) What is the name of this letter e:





- 1)  Waldeyer's lymphatic ring
  - 2)  Palatine tonsils
  - 3)  Lingual tonsil
- 8) What is the name of this cranial nerve:

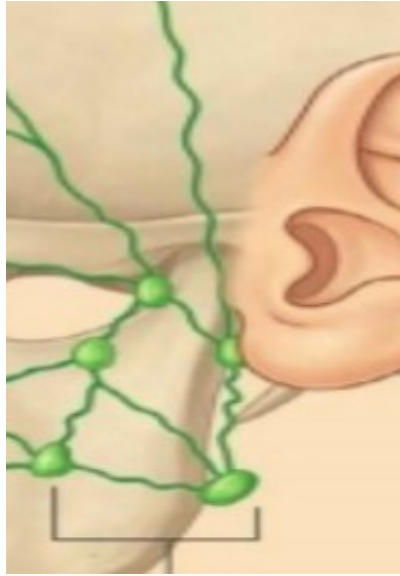


- 1)  Optic
- 2)  Facial



3)  Trigeminal

9) What is the name of this lymph node:

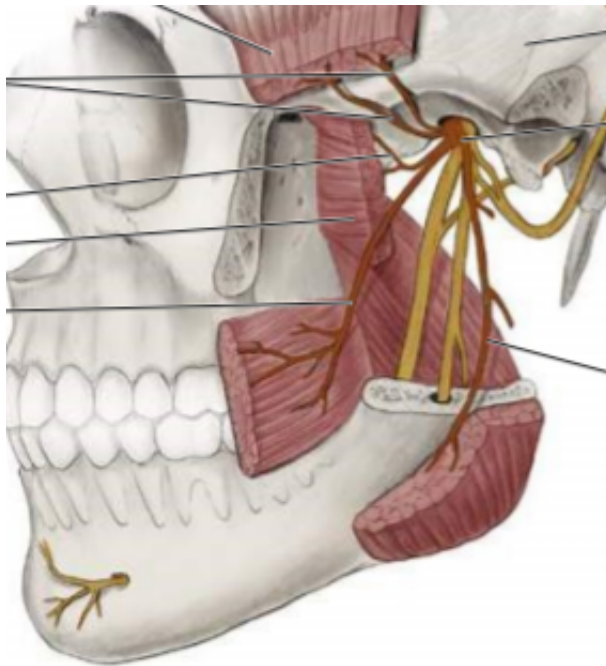


1) - Sublingual

2) - Submandibular

3)  Parotid

10) This branch from which nerve:

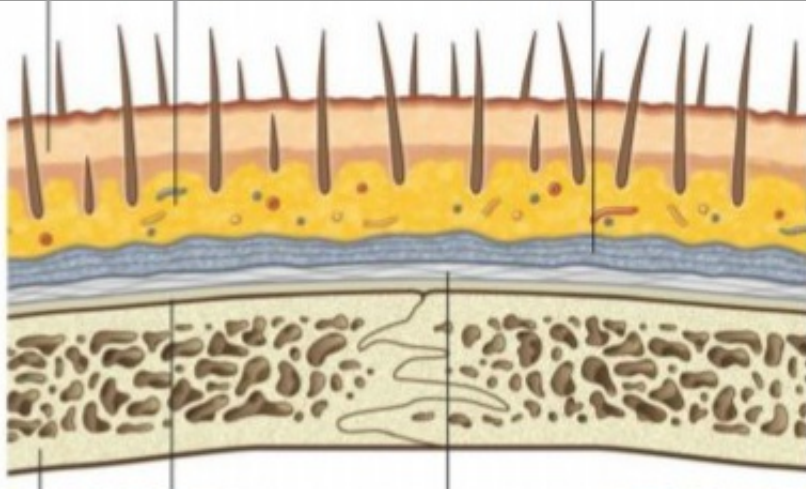


1)  Trigeminal

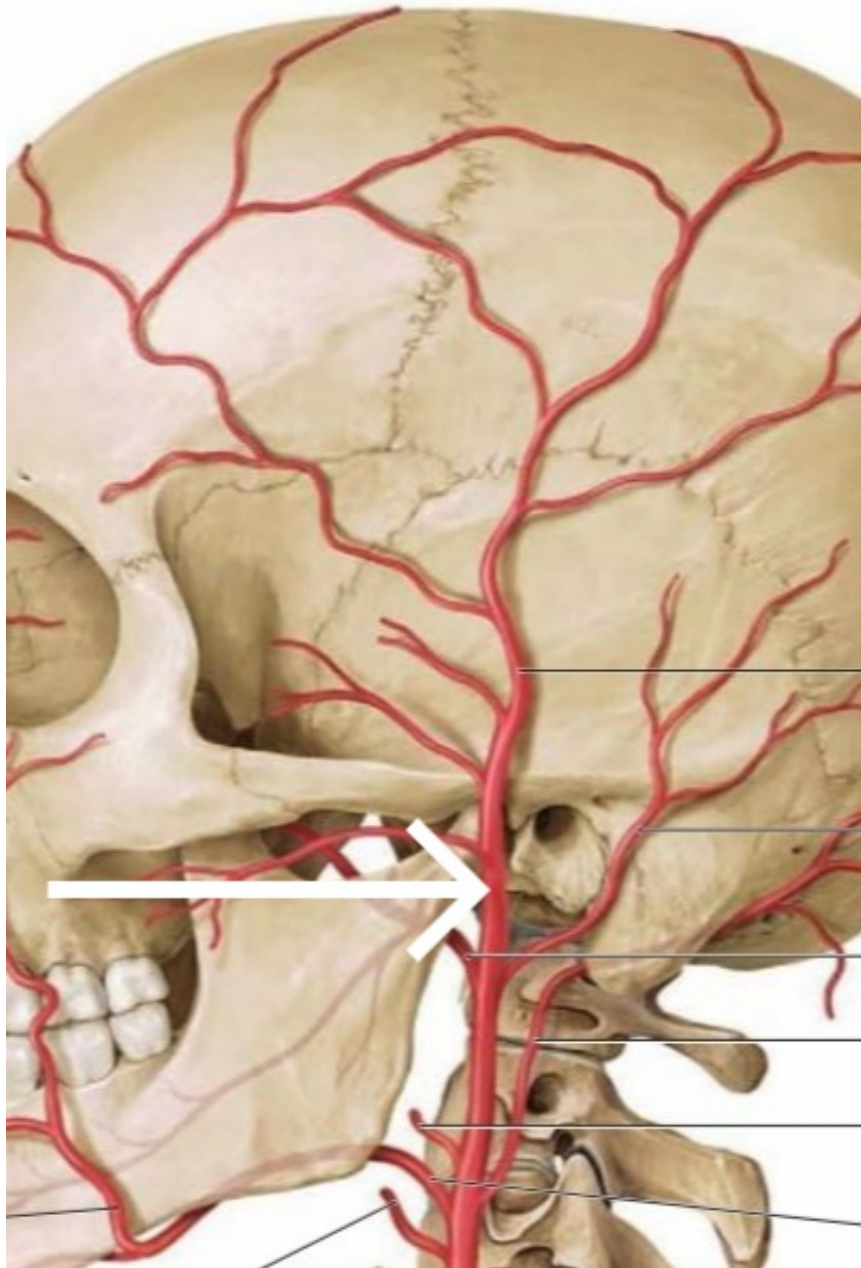
2) - Facial

3) - Vegas

11) What is the dangerous layer of the scalp:



- 1) - Skin
  - 2) - Connective tissue
  - 3) + Loose areolar connective tissue
- 12) This branch is within any of these arteries



- 1) - Internal carotid
  - 2)  External carotid
  - 3) - Common carotid
- 13) what is the name of this muscle

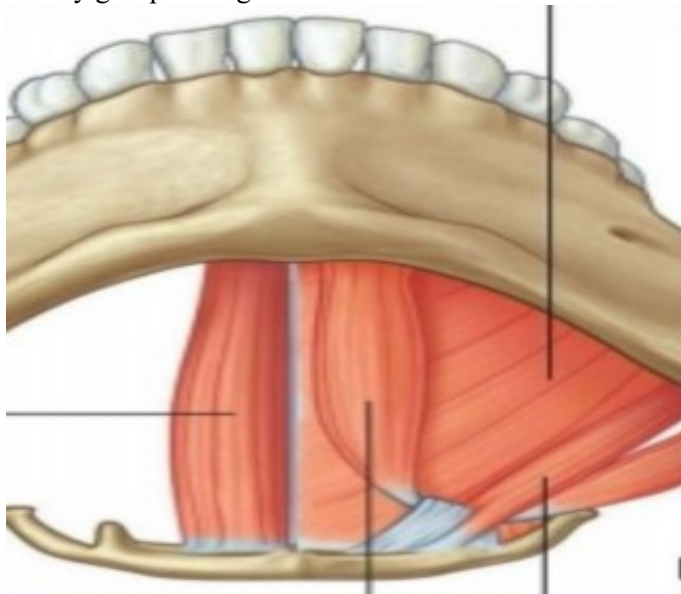




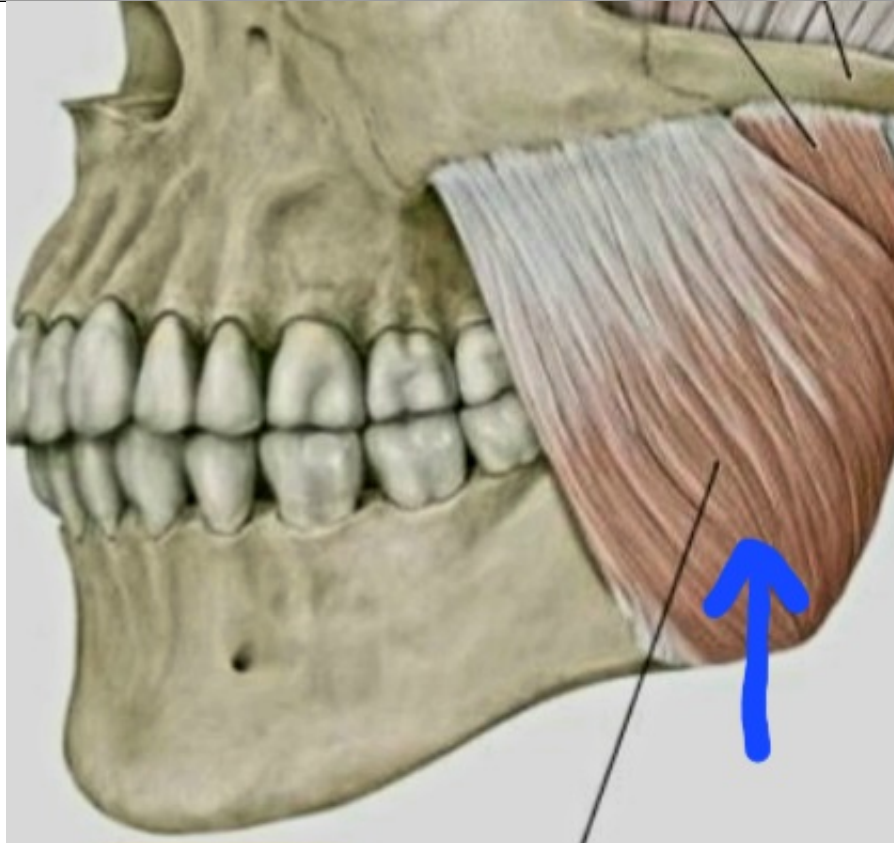
- 1)  Orbicularis oris
  - 2)  Orbicularis oculi
  - 3)  Procerus
- 14) what is the name of this muscle



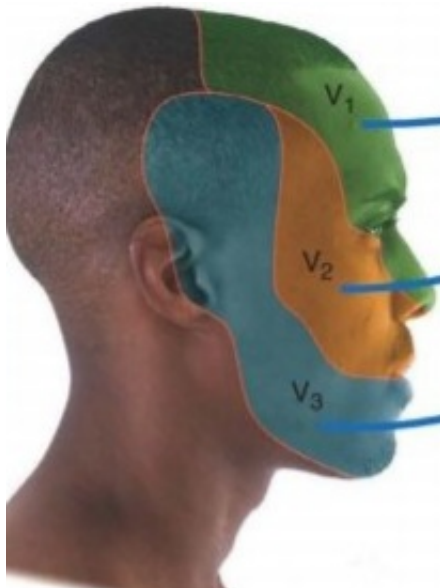
- 1)  Orbicularis oris
  - 2)  Orbicularis oculi
  - 3)  Procerus
- 15) To any group belongs these muscles



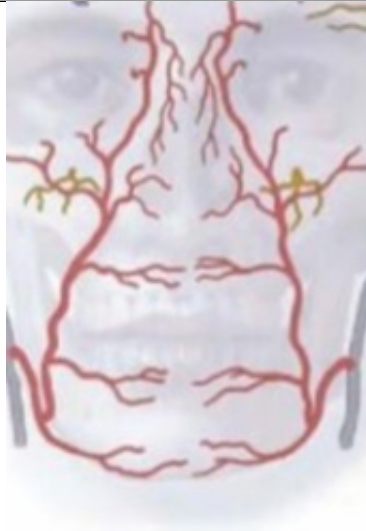- 1)  Supra hyoid Muscles
  - 2)  Infra hyoid Muscles
  - 3)  Superficial muscles of the neck
- 16) what is the name of this muscle



- 1) - deep masseter muscle
  - 2)  superficial masseter muscle
  - 3) - temporalis
- 17) what is the name of this cranial nerve



- 1) - V sensory
  - 2)  V motor
  - 3) - facial
- 18) what is the name of this artery (red)



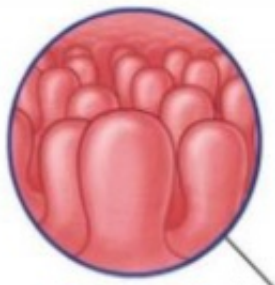- 1) - superficial temporal
- 2) - maxillary
- 3)  facial

19) what is the name of this structure



- 1)  pterygoid plexus
- 2) - cavernous sinus
- 3) - sigmoid sinus

20) what is the name of this papillae



- 1) - filiform
- 2) - foliate
- 3)  fungiform